

# UMN>>LMN, bulbar onset, CNS #47

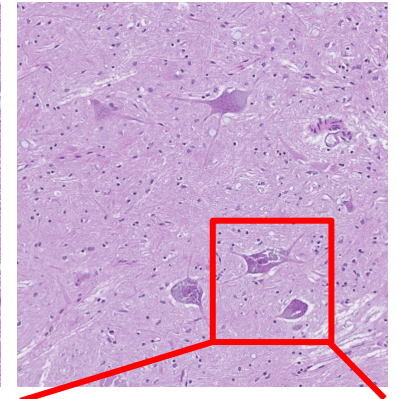
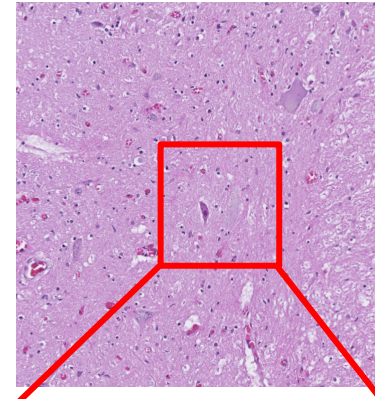
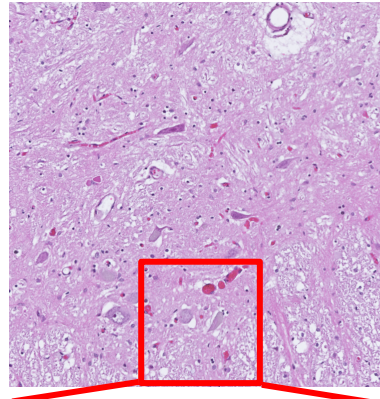
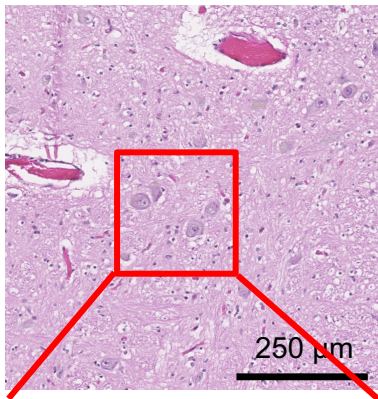
Medulla  
(CNXII)

Cervical

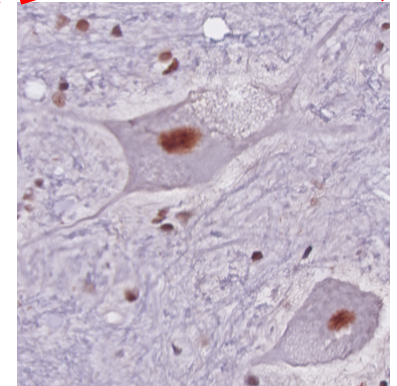
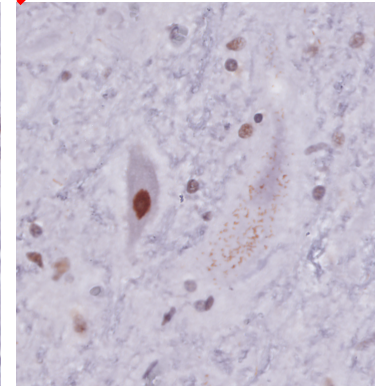
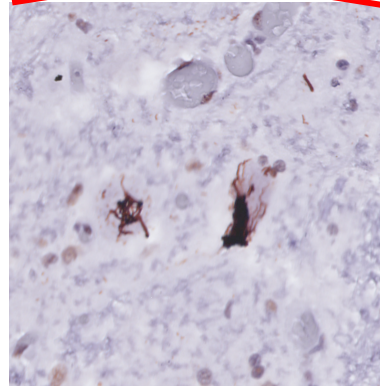
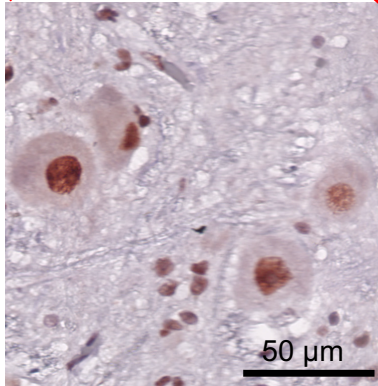
Thoracic

Lumbar

HE

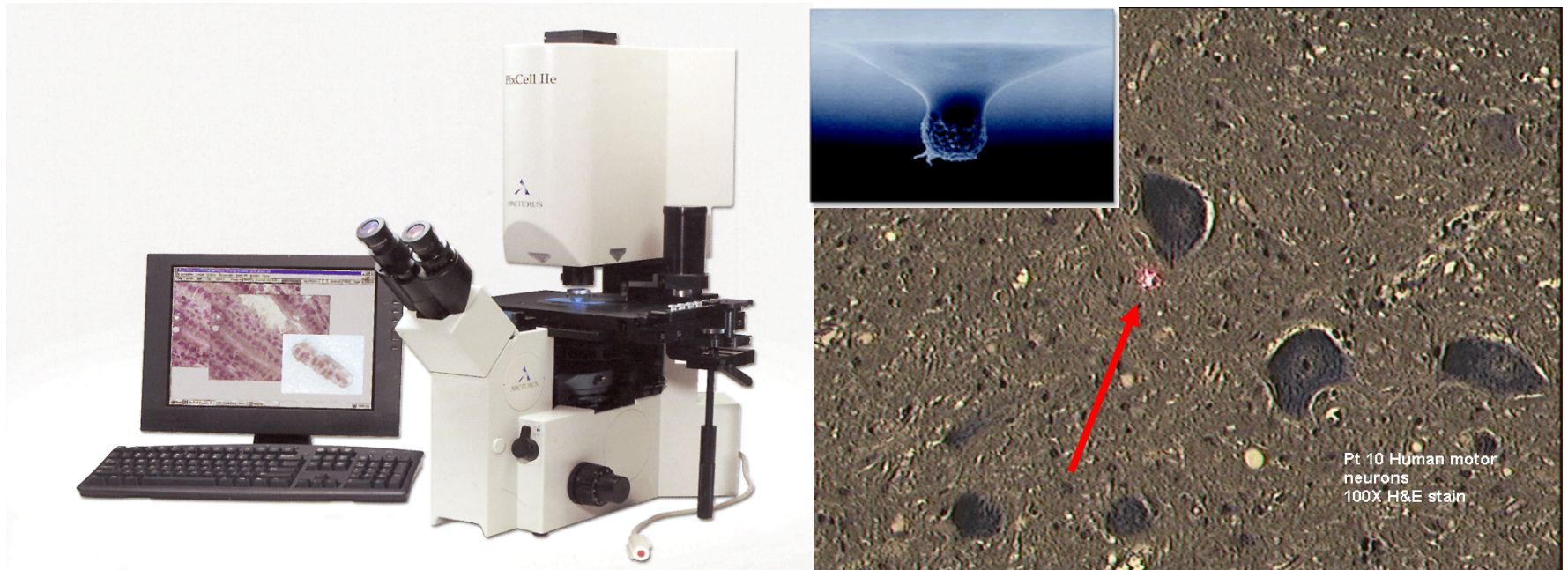


TDP-43  
(N 1-260)



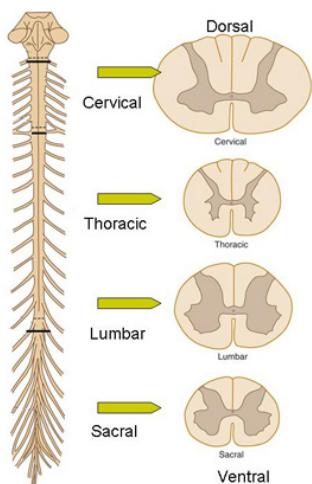

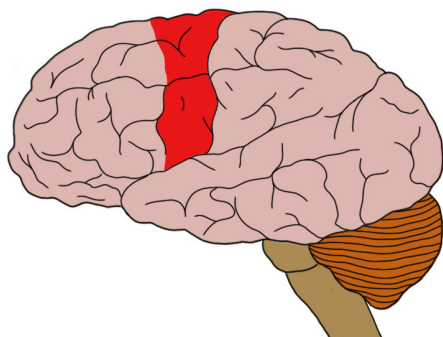
TDP-43 (N 1-260), Ra, Proteintech, 1:5000

# Bridging neuropathology and molecular biology: Laser microdissection

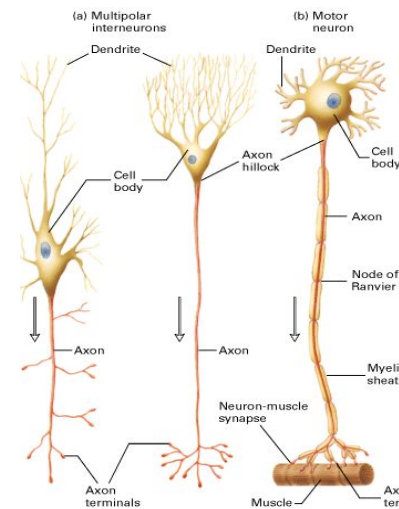
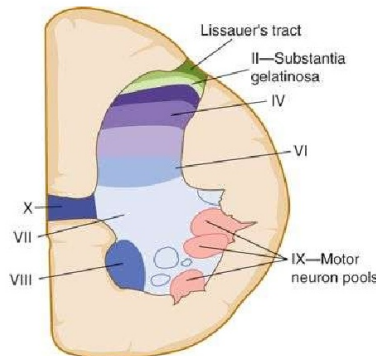


Laser capture microdissection (LCM)

# Gross and Microscopic Anatomy of Motor System: What exactly is degenerating and how quickly?



## Organization: Gray



Source: Waxman SG: *Clinical Neuroanatomy*, 25th Edition; <http://www.accessmedicine.com>  
 Copyright © The McGraw-Hill Companies, Inc. All rights reserved.